

ORIGINAL ARTICLE

## The inverted Batman incision: A new incision in transcolumellar incision for open rhinoplasty

Yuji Nakanishi<sup>1</sup>, Tomohisa Nagasao<sup>2</sup>, Yusuke Shimizu<sup>2</sup>, Junpei Miyamoto<sup>3</sup>, Keizo Fukuta<sup>1</sup> & Kazuo Kishi<sup>2</sup>

<sup>1</sup>Verite Clinic, Osaka and Tokyo, Japan, <sup>2</sup>Department of Plastic Surgery, Keio University Hospital, Tokyo, Japan and <sup>3</sup>Department of Plastic Surgery, Hiroshima University Hospital, Hiroshima, Japan

### Abstract

Columellar and nostril shapes often present irregularity after transcolumellar incision for open rhinoplasty, because of the contracture of the incised wound. The present study introduces a new technique to prevent this complication, and verifies its efficacy in improving cosmetic appearance. In our new method, a zig-zag incision with three small triangular flaps is made on the columella and in the pericolumellar regions of the bilateral nostril rims. Since the shape of the incision resembles the contour of an inverted “batman”, we term our new method the “Inverted Batman” incision. To verify the effectiveness of the Inverted Batman incision, aesthetic evaluation was conducted for 21 patients operated on using the conventional transcolumellar incision (Conventional Group) and 19 patients operated on using the Inverted Batman incision (Inverted Batman Group). The evaluation was performed by three plastic surgeons, using a four-grade scale to assess three separate items: symmetry of bilateral soft triangles, symmetry of bilateral margins of the columella, and evenness of the columellar surface. The scores of the two groups for these three items were compared using a non-parametric test (Mann-Whitney U-test). With all three items, the Inverted Batman group patients present higher scores than Conventional Group patients. The Inverted Batman incision is effective in preserving the correct anatomical structure of the columella, soft triangle, and nostril rims. Hence, we recommend the Inverted Batman incision as a useful technique for open rhinoplasty.

**Key Words:** Plastic surgery, craniofacial

### Introduction

Since the noses of Oriental people are smaller than those of Caucasians, many Oriental persons receive cosmetic surgery to increase the protrusion of the nose, by augmenting nasal tips in the anterior direction [1–3]. Open rhinoplasty is often conducted for this purpose [4–6]. This technique allows the operator to work on nasal cartilages under direct exposure. This operative condition is advantageous in that it enables operators to sculpt the cartilages elaborately. Thereby, operators can produce nose shapes as they intend. In open rhinoplasty, the septal and alar cartilages are exposed after incision of the skin covering them. As the nose is one of the most important human organs in terms of cosmetic impression, great care should be taken in making these incisions, lest conspicuous scars be left there. However, despite care taken during incision, undesirable aesthetic conditions develop in some cases, because of postoperative contracture of operative scars. For instance, in one patient (Figure 1), where open rhinoplasty was conducted through a transcolumellar incision, the bilateral margins of the columella present irregularity; the region of the columella anterior to the incision line protrudes slightly more than the posterior region, presenting a trap-door deformity, and the bilateral soft triangles are asymmetric. To avoid these complications, we modified the transcolumellar incision to develop a new incision method. The present study introduces our technique and verifies its effectiveness in improving cosmetic outcomes.

### Patients and methods

#### *Surgical technique*

First, an incision line—including an inverted V shape—is marked in the central part of the columella (Figure 2a). Then the design of the incision line is extended to the medial aspect of the nostril. A small pit exists between the columellar edge and the medial nasal protrusion (the region marked with a dotted circle in Figure 2c). A small triangle is designed around the pit (Figure 2b). The designed lines are incised, and the flap is elevated, exposing the alar and septal cartilages. The edge of the triangle inside the nostril remains as the positional marker of the initial incision (Figure 2d, arrow). After manoeuvres are applied to augment the shape of the nose, the tips of the bilateral triangular flaps are placed back in their original positions, making sure that the tips of the small triangular flaps match the angle indicated with the arrow in Figure 2d. Thereby, bilateral triangular flaps are sutured to their original positions. The diagram of our design is shown in Figure 3. Since the design is similar to the contour of the head and shoulders of an inverted “batman”—an imaginary comic book hero—we term our design the Inverted Batman incision.

#### *Verification of effectiveness in clinical cases*

The effectiveness of the Inverted Batman incision was verified by referring to 40 patients (32 females and eight males) who had open rhinoplasty. Of the 40 patients, 21 patients (17 females and

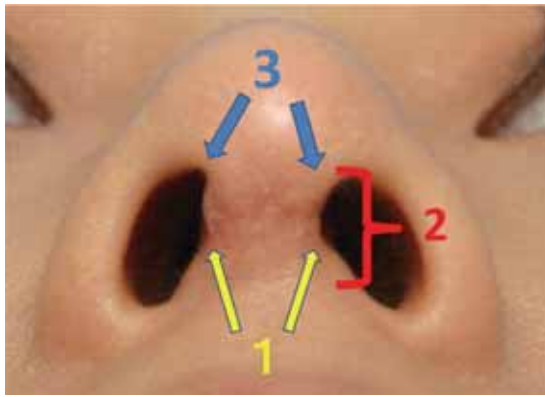


Figure 1. Typical complications of the conventional transcolumellar incision. (1) Irregularity and asymmetry of bilateral columellar margins, (2) conspicuous step between the anterior and posterior sides of the transcolumellar incision, and (3) asymmetry and deformity of bilateral soft triangles are present.

four males) were operated on using the conventional transcolumellar incision, and 19 patients were operated on using the Inverted Batman incision. The former group was termed the Conventional Group and the latter was termed the Inverted Batman Group. The age ranges for the Conventional Group and Inverted Batman Group were  $32.3 \pm 8.4$  years and  $31.0 \pm 7.8$  years, respectively. No statistical difference exists between the two groups. All 40 patients received an operation for cosmetic improvement of the nasal tip. Patients with congenital deformities that could potentially affect the nasal shape—such as cleft lip or craniofacial disorders—were excluded from the study. Representative cases for the Conventional and Inverted Batman Groups are shown in Figures 4 and 5, respectively. Aesthetic evaluation of the patients' noses was conducted for each of the two groups by two plastic surgeons and one otorhinolaryngologist. The three doctors performed aesthetic evaluation of the patients' noses referring to: (1) Symmetry of the soft triangle, (2) Symmetry of columellar margins, and (3) Evenness of the

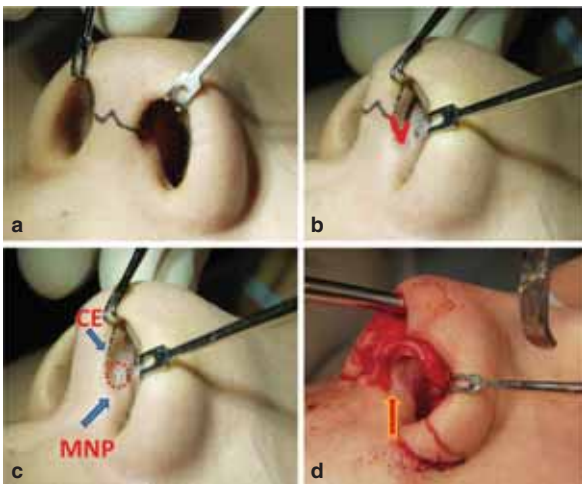


Figure 2. Surgical procedure. (a) An inverted-T incision is designed on the columella. (b) A concavity exists (dotted circle) in the region between the columellar edge (CE) and the medial nostril protrusion (MNP). (c) A small triangular flap is designed along the concavity. (d) The apex point of the triangular flap is used as a guide in suturing the wound.

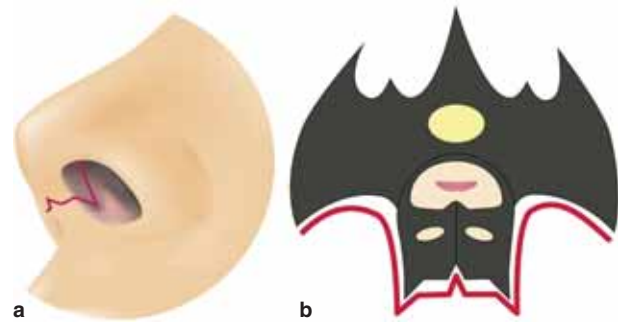


Figure 3. (a) Diagram of our incision method. (b) Our incision line resembles the contour of the head and shoulders of an inverted Batman.

Conventional group

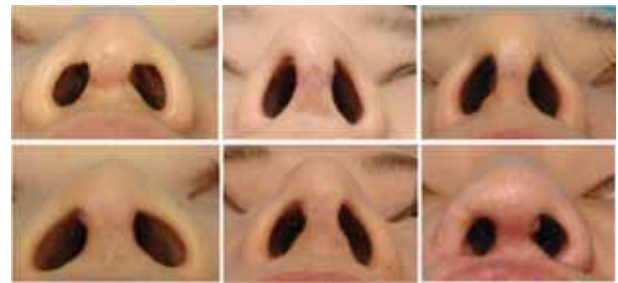

Figure 4. Samples of the Conventional group.

columella. With each of these three items, the three evaluators gave a four-grade score (1 = poor; 2 = fair; 3 = good; 4 = excellent). With each item of each patient, the scores of the three evaluators were summed. Accordingly, each item of each patient was given a score ranging from 3 (whereby all evaluators gave 1 = poor) to 12 (whereby all evaluators gave 4 = excellent). With each of the three items, the scores were compared between the Conventional Group and the Inverted Batman Group. The comparison was performed with the Mann-Whitney U-test using SPSS 11.0 (SPSS Inc., Chicago, IL). *P*-values smaller than 0.05 were considered statistically significant.

### Results

The averages and ranges for the three items are demonstrated in Tables I–III. With all three evaluation items: (1) Symmetry of the soft triangle (Table I), (2) Symmetry of columellar margins (Table II), and (3) Evenness of the columella (Table III), the Inverted Batman Group presented higher scores than the Conventional Group. The difference was statistically significant,

Inverted batman group

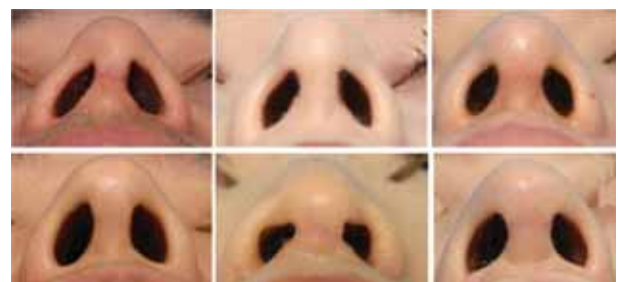

Figure 5. Samples of the Inverted Batman group.

Table I. Symmetry of soft triangle.

	Range (Average)	Statistical significance
Conventional ( $n = 21$ )	3–7 (5.0)	$p < 0.001$
Batman ( $n = 19$ )	9–12 (9.3)	

Table II. Symmetry of columella margins.

	Range (Average)	Statistical significance
Conventional ( $n = 21$ )	3–7 (6.0)	$p < 0.001$
Batman ( $n = 19$ )	8–12 (10.2)	

Table III. Evenness of columella.

	Range (Average)	Statistical significance
Conventional ( $n = 21$ )	3–7 (8.8)	$p < 0.01$
Batman ( $n = 19$ )	9–12 (10.8)	

indicating that the Inverted Batman incision is less likely to result in unsightly scars than conventional incisions.

### Discussion

Two incision methods are usually used for open rhinoplasty. With the first method—called transcolumellar incision—the incision is made in the central part of the columella [7]; with the second method, the incision is made at the labialcolumellar junction [8]. Cleft lip cases previously operated on with the Millard technique have postoperative scars at the labialcolumellar junction [9,10]. For these cases, usage of the second incision method might be an acceptable option. However, in other cases, we prefer the first incision method, because we recognise that scars at the central part of the columella are not evident in the frontal view. Intending to minimise contracture of the scar on the columella, some surgeons modify transcolumellar incisions to form a V-shape or a W-shape [11,12]. They explain that the zigzag effects of the incised wound make the scar inconspicuous. According to this theory, we include an inverted-V design in the transcolumellar incision.

With our method, small triangular flaps are placed in the pericolumellar regions of the bilateral nostril rims. The small triangular flaps correspond to the ears of the “Batman”. This technique—placement of the small triangular flaps—has the following three advantages.

First, placement of the triangular flaps makes it easy for the surgeon to match the incised edges correctly in closing the wound, after working on the cartilages. Cosmetic open rhinoplasty for the Oriental population mainly aims at augmenting the nasal tip. As the nasal tip is repositioned in the anterior direction, the skin on the anterior side of the incision line is expanded. This expansion makes it difficult for the surgeon to match the bilateral margins of the incised wound. This phenomenon is explained in Figure 6. In the figures, point A and point A' are initially counterparts of bilateral margins. Extension of the nasal tip in the anterior direction changes their positional relationship. As the nasal tip is repositioned anteriorly, the skin anterior to the incision line is pulled in the anterior direction. Accordingly, point A' moves in the anterior direction (Figures 6a,b,c). If the incised wound is sutured in this condition, bilateral margins are wrongly matched. Hence, the wound is highly likely to develop hypertrophic change postoperatively.

On the other hand, with the Inverted Batman incision, point A' is easily identifiable even after the nasal tip is moved in the anterior direction, as shown with the arrow in Figure 2f. By making sure that the tip of the small triangular flap (point A) corresponds to point A', accurate matching of the bilateral margins is secured (Figures 6d,e,f). It could be argued that anterior repositioning of point A' is favourable to reduce tension that develops on the columella skin accordingly as the nasal tip is advanced in the anterior direction. However, our experience shows dissection of the columella skin and nasal cartilages enables effective advancement of the nasal tip even when point A' stays at its initial position. Because of the optimal matching of the wound margins, the Inverted Batman incision achieves better symmetry with the soft triangle and bilateral edges of the columella than the conventional incision.

The second advantage of the Inverted Batman incision is that it lowers the risk of trap-door deformities on the columella. Since the skin inside the nostril has dense sebaceous glands and hair follicles, wounds made inside the nostril are likely to develop minor infection and subsequent contracture. When contracture occurs, unevenness develops on bilateral sides of the incised wound (Figures 7a and b). However, with the Inverted Batman incision, the effect of the contracture is buffered because of the zig-zag effect of the small triangular design, making trap-door deformity unlikely to happen (Figures 7c and d).

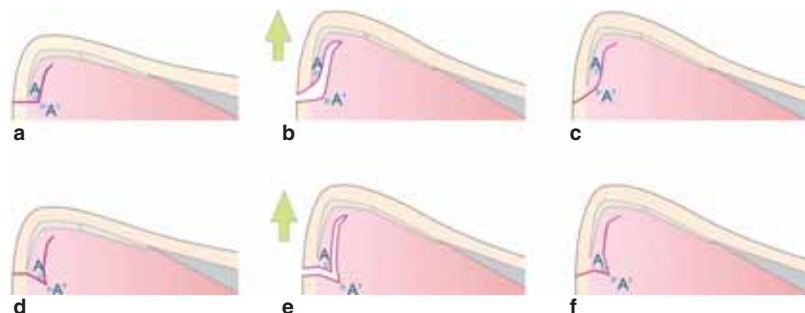


Figure 6. (a–c) With the conventional transcolumellar incision, the positional correspondence of the bilateral margins of the incision are likely to be impaired as the nasal tip is advanced in the anterior direction. (d–f) With the Inverted Batman incision, accurate matching of the bilateral margins is secured.

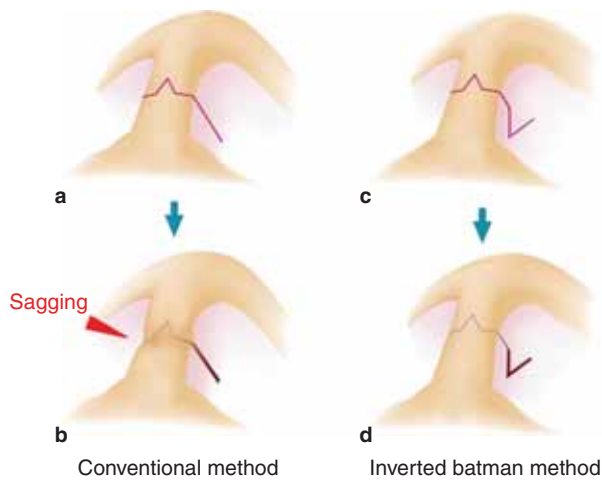


Figure 7. (a, b) With the conventional transcolumnellar incision, the columella is pulled by the contracture of the intranostril wound and sags. (c, d) With the Inverted Batman incision, the sagging of the columella does not occur.

The third advantage of the Inverted Batman incision is that it does not destroy the anatomical structure of the pericolumellar region. In this region of the nostril, a small pit exists above the medial nasal protrusion, as shown in Figure 2b. With conventional incision—where the incision line crosses this pit—the structure of the pit is interrupted. On the other hand, since the incision line skirts the pit with the Inverted Batman incision, the anatomical structure of the pit is preserved.

Raising the small triangular flap inside the nostril requires meticulous manoeuvring, extending operation time by several minutes. However, the additional several minutes pays well, delivering convenience in closing the incised wound and inconspicuous scarring. For these advantages of the Inverted Batman

incision, we recommend it as an effective surgical technique for open rhinoplasty.

**Declaration of interest:** The authors report no conflicts of interest. The authors alone are responsible for the content and writing of the paper.

## References

- [1] Hwang TS, Kang HS. Morphometry of nasal bases and nostrils in Koreans. *Ann Anat* 2003;185:189–93.
- [2] Jin HR, Won TB. Nasal tip augmentation in Asians using autogenous cartilage. *Otolaryngol Head Neck Surg* 2009;140: 526–30.
- [3] Chang YL. Correction of difficult short nose by modified caudal septal advancement in Asian patients. *Aesthet Surg J* 2010;30: 166–75.
- [4] Cho BC. Correction of unilateral cleft lip nasal deformity in preschool and school-aged children with refined reverse-U incision and V-Y plasty: long-term follow-up results. *Plast Reconstr Surg* 2007;119:267–75.
- [5] Dutton JM, Bumsted RM. Management of the cleft lip nasal deformity. *Facial Plast Surg Clin North Am* 2001;9:51–8.
- [6] Maguire AJ. Open rhinoplasty approach to the deviated nose. *Facial Plast Surg* 1989;6:83–7.
- [7] Prado Neto Jde M, Jung KS. Secondary rhinoplasty via transcolumnellar incision. *Aesthetic Plast Surg* 1992;16:21–5.
- [8] Spiro SA, Wolfe SA, Wider TM. The use of the labiocolumellar crease incision in rhinoplasty. *Ann Plast Surg* 1996;37:569–76.
- [9] Millard DR Jr, Morovic CG. Primary unilateral cleft nose correction: a 10-year follow-up. *Plast Reconstr Surg* 1998; 102:1331–8.
- [10] Mohler LR. Unilateral cleft lip repair. *Plast Reconstr Surg* 1987; 80:511–17.
- [11] Aksu I, Alim H, Tellioglu AT. Comparative columellar scar analysis between transverse and inverted-V incision in open rhinoplasty. *Aesthetic Plast Surg* 2008;32:638–40.
- [12] Celik M, Tuncer S, Eryilmaz E. Running W incision in open rhinoplasty: better scar quality. *Aesthetic Plast Surg* 2003;27: 388–9.